

Intracranial abscess secondary to dental infection

We report a case of *Aggregatibacter actinomycetemcomitans* (*A. actinomycetemcomitans*) bacteraemia and secondary brain abscess in a patient where periodontal disease was implicated as the probable source.

Keywords

Brain abscess; periodontal disease; *Aggregatibacter actinomycetemcomitans*.

Journal of the Irish Dental Association 2014; 60 (1): 32-34.

Paul Brady

BDS MFDS MSc Con Sed
Clinical Fellow
Department of Oral Surgery
Cork University Dental School and
Hospital

Sarah Bergin

LRCP & SI MB BCH BAO (NUI) MICGP
Specialist Registrar Microbiology
Department of Clinical Microbiology
Cork University Hospital

Dr Bartley Cryan

MB FRCPI FRCPath MD M MSc
Consultant Microbiologist
Department of Clinical Microbiology
Cork University Hospital.

Oisín Flanagan

MB BCH BAO BMedSci MRCPI FFR
Specialist Registrar Radiology
Department of Radiology
Cork University Hospital

Address for correspondence

Paul Brady
Clinical Fellow
Department of Oral Surgery
Cork University Dental School and
Hospital
Wilton
Cork
E: paul.brady@ucc.ie

Introduction

The oral cavity is considered as being home to a rich and abundant microflora, including *Aggregatibacter actinomycetemcomitans* (*A. actinomycetemcomitans*), which is recognised as one of the major pathogens in destructive periodontal disease.¹ A cerebral abscess linked to a dental source is a rare occurrence, since in most individuals the blood-brain barrier, along with the immune response, will exclude bacteria. In this age of antibiotics and with modern living conditions, pyogenic brain infections of odontogenic origin are uncommon in western society. It has been postulated that oral microorganisms may enter the cranium by several pathways: 1) by direct extension, 2) by haematogenous spread, 3) by local lymphatics, and 4) indirectly, by extraoral odontogenic infection. Brain abscesses thought to be of dental origin have been reported to have a lethal outcome.²

Clinical relevance

The majority of brain abscesses secondary to odontogenic infection occur following dental treatment.³ This report documents an abscess prior to dental treatment, signifying the dangers of untreated dental infection. In this case, and as described previously, molecular identification techniques, i.e., partial sequencing of 16S rDNA of clinical samples, may be helpful for detection and identification of pathogens.⁴ *A. actinomycetemcomitans* is an important

pathogen to consider as a causative agent of brain abscess in those with poor dental health.

Case report

A 68-year-old man was admitted to Cork University Hospital (CUH) following general medical practitioner (GP) referral with a two-day history of sudden onset slurred speech, left-sided facial droop, and left upper limb weakness. He had no relevant past medical history. He did not smoke or drink alcohol. He was not taking any medications. He lived alone in poor social circumstances.

On examination he was alert and orientated. He was dysarthric, his Glasgow Coma Scale was 15/15, blood pressure was 143/75mmHg (BP was 170/111 in the GP surgery), pulse rate was 86 beats per minute regular, temperature 36.8°C. A left-sided VII nerve palsy was noted. He had reduced power, reflexes and tone in both his upper and lower left limbs. A pan-systolic murmur radiating to the axilla was noted. He was noted to have very poor dentition by the admitting staff. The rest of his examination was within normal limits.

Laboratory investigations revealed a normal white cell count, and his C-reactive protein was 78mg/L. A provisional diagnosis of cerebral vascular accident, possibly secondary to hypertensive disease, was made. However, CT brain revealed a ring enhancing lesion in the right frontal lobe, in keeping with a brain abscess (Figure 1).

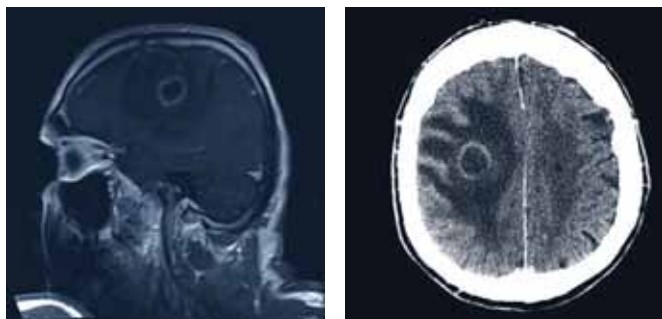


FIGURE 1: Post-contrast CT brain. The lesion shows rim enhancement in keeping with an abscess.

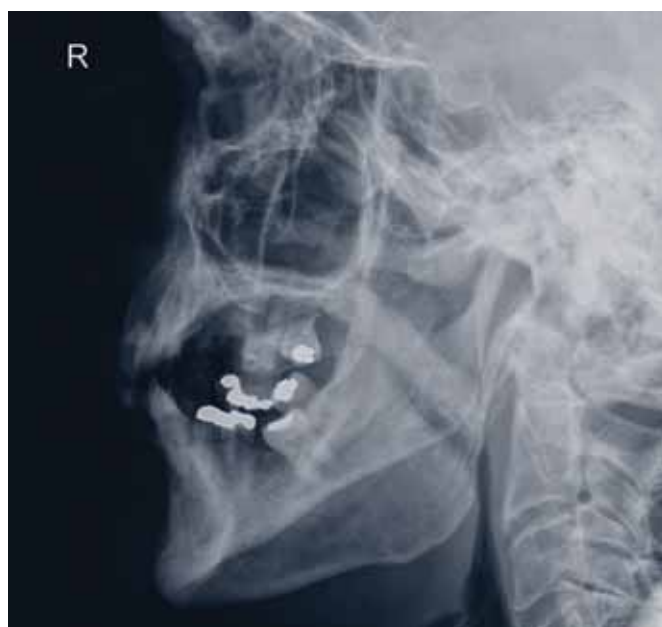

FIGURE 2: Lateral mandible at presentation. Note the poor upper and lower dentition.

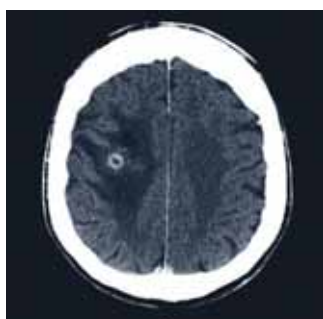


FIGURE 4: CT brain post contrast one month post debulking of brain abscess. Note decrease in size of ring enhancing lesion.

In view of this diagnosis and the presence of the murmur, multiple blood cultures were taken to rule out endocarditis as a source of infection. On further questioning, the patient described left-sided facial swelling and non-traumatic loss of a tooth one week prior to admission.

Empiric therapy with meropenem, vancomycin and IV dexamethasone was commenced. The patient underwent craniotomy

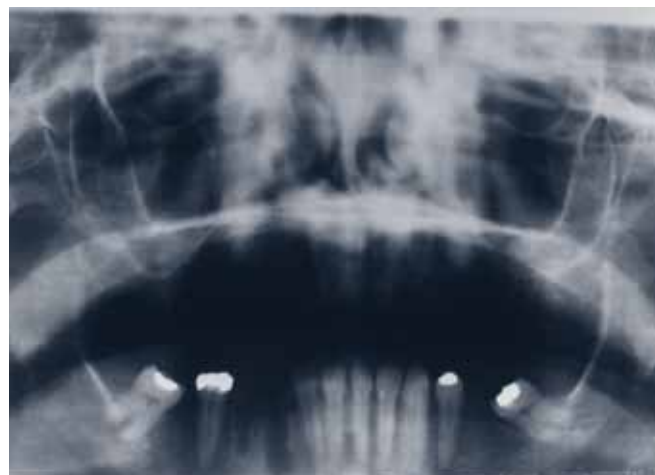

FIGURE 3: OPG post extraction showing healing sockets.

and ultrasound-guided drainage of the brain abscess on day three after admission. The organisms from the blood culture and brain abscess aspirate failed to identify satisfactorily using Analytical Profile Index (for quick identification of clinically relevant bacteria), and so were sent for molecular testing. *A. actinomycetemcomitans* was identified from both blood cultures and the fluid from the brain abscess by partial sequencing of 16S rDNA by the Molecular Identification Service at the HPA Colindale, London. Transoesophageal echocardiogram revealed moderate to severe mitral regurgitation but no vegetations. A dental review was requested by the neurosurgical team. A clinical examination revealed multiple carious and periodontal involved teeth in the maxilla. An OPG radiograph was requested; however, the patient was unable to maintain an upright position to facilitate this. Therefore, lateral and oblique views were taken. The radiographs showed the presence of what appeared to be destructive periodontal disease and dental caries, particularly in the maxillary posterior teeth (Figure 2).

On day four following admission the patient was brought to theatre and had a dental clearance in the maxilla and two left mandibular teeth removed under general anaesthetic. The teeth extracted were mostly periodontally infected with extensive dental caries. Therefore, it is postulated that periodontal disease was the original source of infection in this patient (Figure 3).

Antibiotic therapy with meropenem was continued for six weeks. Repeat CT scans showed gradual resolution of the brain lesion (Figure 4). The patient underwent intensive rehabilitation with physiotherapy and occupational therapy. At discharge he still had some left-sided weakness and was not well enough for independent living, and therefore went to sheltered housing. He will be followed up with the neurosurgery and cardiology services in CUH.

Discussion

A. actinomycetemcomitans is a member of the *Haemophilus*, *Actinobacillus*, *Cardiobacterium*, *Eikenella*, and *Kingella* (HACEK) group of microorganisms. This group of organisms has a predilection

for causing infective endocarditis.⁵ It was first described as a human pathogen in 1912. It is a facultative anaerobic, non motile, coccoid to coccobacillary Gram-negative rod and may look like Morse code on the Gram stain. The organism is fastidious and slow growing, which makes it difficult to culture. Material should be incubated on blood and chocolate agar in an enhanced (5-10%) CO₂ atmosphere for at least 48 hours. On a blood agar plate, the small colonies may stick to the medium and may form a star structure at the centre of a mature colony. In blood cultures, the organism often grows slowly in small 'granules' adherent to the sides of the bottles, with the rest of the medium remaining clear. Prolonged incubation of blood cultures up to 21 days is recommended if endocarditis caused by fastidious organisms is suspected.

A. actinomycetemcomitans has been described as a cause of meningitis, brain abscess, endophthalmitis (with and without concomitant endocarditis), soft tissue infections, septic arthritis, osteomyelitis, and endocarditis. It may be part of the endogenous flora of the mouth and can be recovered from about 20% of healthy teenagers and adults.⁵ It is normally found in dental plaque, periodontal pockets and gingival sulcus, and is one of the major pathogens in adult and juvenile forms of periodontitis. It is present in more than 50% of adults with refractory periodontitis and 90% of patients with localised aggressive periodontitis.^{5,6} This organism produces a number of virulence factors that contribute to periodontal disease. Leukotoxin modulates host inflammatory responses, which leads to local tissue destruction and *A. actinomycetemcomitans* lipopolysaccharides stimulate macrophages to release interleukins and tumour necrosis factor, which stimulate bone resorption.⁶ In a recent review of the literature by Rahamat-Langendoen *et al.*, there were 12 reported cases of brain abscesses due to *A. actinomycetemcomitans*, and in six patients, the most probable source of infection was poor dentition or recent dental therapy.⁴

The optimal treatment of brain abscesses consists of surgical drainage of the collection combined with antimicrobial therapy.⁶ *A. actinomycetemcomitans* displays variable susceptibility to penicillin. It is usually susceptible to cephalosporins, aminoglycosides, fluoroquinolones, tetracyclines and chloramphenicol; however, third generation cephalosporins are considered the drug of choice for serious infection. Susceptibility testing is recommended; however, this may be difficult due to the slow growing and fastidious nature of the organism. Severe *A. actinomycetemcomitans*-associated periodontitis is usually treated with mechanical debridement in combination with oral tetracycline therapy.⁵

In conclusion, *A. actinomycetemcomitans* is an important pathogen in cases of brain abscess associated with poor dentition. This case highlights the importance of performing a detailed examination of the oral cavity in patients presenting with intracranial infections. Maintenance of good periodontal health through oral hygiene measures and professional dental care will assist in focusing on a positive association from preventing and treating periodontal disease as a means of ameliorating serious systemic infection. Hence, researchers must continue not only to uncover more information

about the correlations between periodontal and systemic diseases, but also to focus on positive associations that may result from treating periodontal disease as a means of ameliorating systemic diseases.

Simple oral healthcare tasks, such as brushing and flossing, and limiting other risk factors, such as smoking, may assist in initially decreasing periodontal pockets and periodontal bacterial flora, consequently decreasing the likelihood of the progression of periodontal disease in causing detrimental systemic disease.

References

1. Zambon, J.J. *Actinobacillus actinomycetemcomitans* in human periodontal disease. *J Clin Perio* 1985; 12: 1-20.
2. Antunes, A.A., de Santana Santos, T., de Carvalho, R.W., Avelar, R.L., Pereira, C.U., Pereira, J.C. *Journal of Craniofacial Surgery* 2011; 22 (6): 2363-2365.
3. Asensi, V., Alvarez, M., Carton, J.A., Lago, M., Maradona, J.A., Asensi, J.M., *et al.* *Eikenella corrodens* brain abscess after repeated periodontal manipulations cured with imipenem and neurosurgery. *Infection* 2002; 30: 240-242.
4. Rahamat-Langendoen, J.C., van Vonderen, M.G.A., Engstrom, L.J., Manson, W.L., *et al.* Brain abscess associated with *Aggregatibacter actinomycetemcomitans*: case report and review of literature. *J Clin Periodontol* 2011; 38: 702-706.
5. Steinberg, J.P., Burd, E.M. Other Gram-negative and Gram variable bacilli. In: Mandell, G.L., Bennett, J.E., Dolin, R. (eds.) *Principles and Practice of Infectious Diseases* (7th Ed.). Elsevier, 2010: 3015-3033.
6. Kesic, L., Petrovic, M., Obradovic, R., Pejicic, A. The importance of *Aggregatibacter actinomycetemcomitans* in etiology of periodontal disease – mini review. *Ata Medica Medinæ* 2009; 48 (3): 35-37.