Current advances in the treatment of giant cell arteritis: the role of biologics

Ther Adv Musculoskel Dis
2019, Vol. 11: 1–11
DOI: 10.1177/1759720X19827222

© The Author(s), 2019.
Article reuse guidelines: sagepub.com/journals-permissions

Candice Low and Richard Conway

Abstract: Giant cell arteritis (GCA) is the most common form of systemic vasculitis. It is a potentially severe disease with 25% of patients suffering vision loss or stroke. Our treatment paradigm is based on glucocorticoids. Glucocorticoids are required in high doses for prolonged periods and subsequently are associated with a significant amount of treatment-related morbidity. Alternative treatment options are urgently needed to minimize these glucocorticoid adverse events. Many other agents, such as methotrexate and tumour necrosis factor alpha inhibitors have been used in GCA, with limited or no evidence of benefit. Our emerging understanding of the pathogenic processes involved in GCA has led to an increased interest in the use of biologic agents to treat the disease. Two randomized controlled trials have recently reported dramatic effects of the use of the interleukin-6 targeted biologic tocilizumab in GCA, with significant increases in remission rates and decreases in glucocorticoid burden. While encouraging, longer-term and additional outcomes are awaited to clarify the exact positioning of tocilizumab in the treatment approach. Emerging data for other biologic agents, particularly abatacept and ustekinumab, are also encouraging but less well advanced. We are at the dawn of a new era in GCA treatment, but uncertainties and opportunities abound.

Keywords: Giant cell arteritis; vasculitis; biologics; tocilizumab; ustekinumab; abatacept

Received: 12 September 2018; revised manuscript accepted: 19 December 2018.

Correspondence to:
Richard Conway
Department of Rheumatology, St. James Hospital, Dublin, Ireland Department of Rheumatology, Suite 2, Blackrock Clinic, Rock Road, Co. Dublin, Ireland
drrichardconway@gmail.com

Candice Low
Centre for Arthritis and Rheumatic Diseases, St. Vincent's University Hospital, Dublin Academic Medical Centre, Dublin, Ireland

Introduction

Giant cell arteritis (GCA) is the most common form of systemic vasculitis. GCA occurs in those over the age of 50 and becomes increasingly common with ageing.[1] GCA can affect any medium or large artery and has a particular predilection for the aorta and its extracranial branches.[2] While the most common features of GCA are headache and polymyalgia, GCA is a potentially devastating disease with up to 25% of patients suffering vision loss or stroke.[3] In the longer-term, aneurysmal disease resulting from vascular inflammation is a major cause of morbidity and mortality.[4] Aortic aneurysm is the most common of these, occurring in 18% of patients; aortic dissection occurs in 5% of patients and is associated with a significantly reduced median survival of 1.6 years.[4,5] Pathologically, GCA is characterized by a granulomatous inflammatory infiltrate.[2] The pathogenesis remains to be fully elucidated with both the innate and adaptive immune systems appearing to play a role.[6] Emerging evidence implicates a dual T-lymphocyte pathway with important roles for T_H1- and T_H17-driven inflammatory cascades.[7] The fact that the pathogenesis is both complex and incompletely understood has played a role in the limitations of current treatment options. Our emerging understanding of the pathogenesis of GCA will hopefully enhance the treatment approach in this disease. Our treatment of GCA has been based to date almost entirely on glucocorticoids. Multiple agents have offered promise, but ultimately little or no evidence of clinical efficacy. High-quality recent evidence has emerged showing preliminary efficacy of a number of biologic agents in GCA. Physicians treating patients with GCA should be aware of these

Box 1. Search strategy for review.

We searched PubMed for the terms 'giant cell arteritis' OR 'temporal arteritis' AND 'biologic' OR 'treatment'. Reference lists of obtained studies were also screened for additional relevant articles.

Creative Commons Non Commercial CC BY-NC: This article is distributed under the terms of the Creative Commons Attribution-NonCommercial 4.0 License (http://www.creativecommons.org/licenses/by-nc/4.0/) which permits non-commercial use, reproduction and distribution of the work without further permission provided the original work is attributed as specified on the SAGE and Open Access pages (https://us.sagepub.com/en-us/nam/open-access-at-sage).

developments. Details of the search strategy used for this review are given in Box 1.

Treatment of GCA

The treatment of GCA in terms of both chronology and the individual patient is characterized by early successes followed by later difficulties and complications. Glucocorticoids were introduced to the treatment paradigm nearly 70 years ago and remain the cornerstone of treatment. Multiple other agents have either had a less than anticipated benefit, been ineffective or even harmful.[8–10] For the individual patient, dramatic early treatment responses are tempered by later treatment-related complications and relapses.[11–13]

Glucocorticoids

Glucocorticoids were first used in GCA by Horton in 1949.[14] Formal confirmation of their efficacy was demonstrated by Shick in the 1950s.[15] Glucocorticoids rapidly improve symptoms and normalize inflammatory markers in GCA and are recommended as the treatment of choice in GCA in consensus guidelines.[16,17] Glucocorticoids are required in high doses for prolonged periods in order to induce and maintain remission in GCA; however, there is considerable uncertainty over the optimum dosing and tapering schedules.[18] Most guidelines recommend commencing on a dose of 40–60 mg daily with a subsequent individualized tapering regime adjusted if necessary by symptoms and adverse events.[16,17] This tapering regime is adjusted on an individual basis and may require temporary increases in steroid doses in the event of relapses. As is evident from the doses illustrated in this regime, patients with GCA receive a high median cumulative steroid dose, equivalent to 6.5 g of prednisolone.[12] Glucocorticoids incompletely extinguish the vascular inflammation in GCA as evinced by findings in animal and autopsy studies.[19,20] A study of repeat Temporal artery biopsies (TABs) in patients treated with high-dose glucocorticoids for GCA showed evidence of persistent vascular inflammation in 75% of patients at 6 months and 44% at 12 months, despite clinically well-controlled disease activity.[21] The consequences of this persistent vascular inflammation include risks of disease relapse and the development of long-term complications such as aortic aneurysms.[5,22] Glucocorticoids are associated with significant treatment-related complications in up to 95% of patients.[11,12] These adverse events are frequently serious and even life-threatening developments such as fractures, diabetes mellitus, hypertension and sepsis.[11,12] Glucocorticoids remain indispensable in the treatment of GCA and provide a rapid and effective treatment; however, they are associated with short-term and long-term complications and patients continue to experience overt relapses and subclinical disease progression. Therefore, other treatment modalities are urgently needed.

Methotrexate

Methotrexate is the recommended first-line treatment and anchor drug in the management of rheumatoid arthritis.[23,24] It is also effective in a wide range of other systemic inflammatory diseases and was a natural candidate for study as a treatment in GCA.[25] There has been conflicting evidence of methotrexate's efficacy in GCA. Two randomized controlled trials (RCTs) showed no effect, whereas one reported reduced relapse rates and lower glucocorticoid doses with methotrexate. All of these studies had a number of potential limitations including the small number of patients recruited, ranging from 21 to 98 patients.[26–28] An individual patient data meta-analysis of the three studies reported lower relapse rates (hazard ratio 0.65, $p = 0.04$), lower cumulative glucocorticoid doses (mean –842 mg at 48 weeks), and a higher rate of glucocorticoid-free remission (hazard ratio 2.8, $p = 0.001$) with methotrexate.[8] The evidence of efficacy from this meta-analysis has to be tempered by the realization of the relatively high numbers needed to treat (10 to prevent one cranial relapse of GCA) and the lack of evidence of a decrease in adverse events with its use.[8] In clinical practice, methotrexate is unlikely to be sufficient to result in a meaningful benefit for the majority of GCA patients.

Synthetic immunosuppressants

Other synthetic immunosuppressants, including azathioprine, leflunomide, mycophenolate mofetil, hydroxychloroquine, dapsone and cyclophosphamide, have also been used in GCA. However, the evidence supporting their use is largely limited to case series.[29–35] One small non-randomized double-blind study of azathioprine in patients with either PMR or GCA showed a significant reduction in mean steroid dose over 52 weeks.[36] An RCT of hydroxychloroquine published in abstract form showed no evidence of efficacy.[37] Cyclosporin A did not demonstrate a

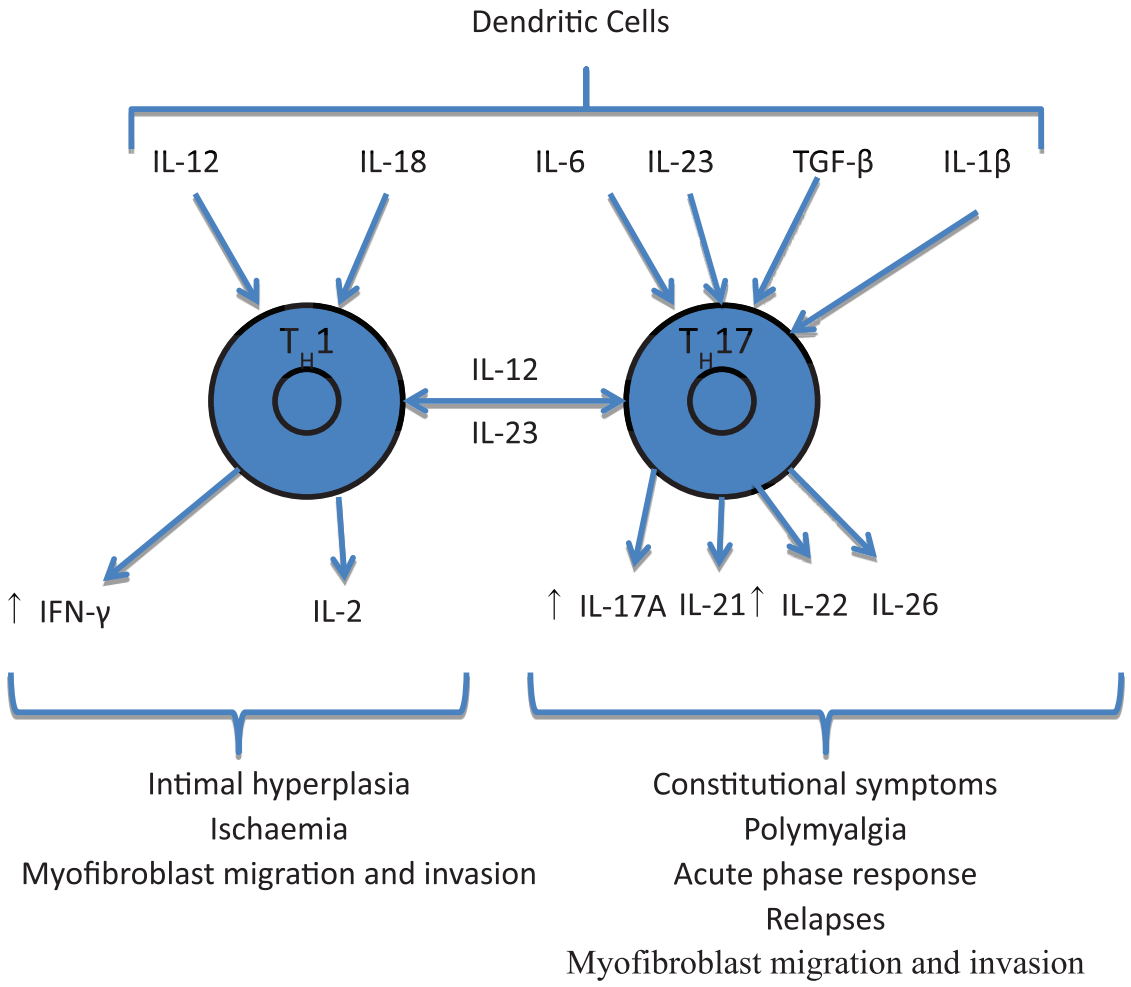

Figure 1. Proposed pathogenic model in GCA.

significant steroid-sparing effect in two randomized open-label studies.[38,39]

Why has it been so difficult to find an effective treatment for GCA?

The explanation for the difficulties in finding an effective treatment for GCA is multifaceted. Factors such as the relative rarity of the disease and the limited extent of research interest in the area, with a small number of groups of dedicated active researchers, have played their part. However, the factors involved run deeper than this. To a large extent, until recently the majority of treatments were repurposed from other rheumatic diseases, particularly rheumatoid arthritis. While there are certain similarities between the diseases, it is perhaps not overly surprising that many of these treatments did not translate to what is a distinct disease area. An interacting and even more important factor relates to the underlying pathogenesis of GCA.

Pathogenesis of GCA

The pathogenesis of GCA remains to be fully elucidated and significant work is ongoing in this area. Despite our evolving knowledge, what has become increasingly clear is that the processes and pathways involved are complex, adding an extra level of difficulty in finding an effective treatment option. The current hypothesis of GCA pathogenesis implicates dual T-lymphocyte pathways, illustrated in Figure 1. The full discussion of GCA pathogenesis is beyond the scope of the current article and we direct interested readers to previously published reviews.[6,7,40,41] This is an added complication as, if this hypothesis is correct, a truly effective treatment approach will either need to target both pathways with a single agent, or alternatively will require a combination of two agents. Fortuitously, existing biologic agents are available which have the potential to target both limbs of this pathogenic model. We will now proceed to discuss potential biologic

treatment options in GCA, with particular reference to those that target the pathways implicated in the pathogenic model, namely tocilizumab (interleukin-6), abatacept (T-lymphocytes), and ustekinumab (interleukin-12/interleukin-23).

Biologic agents

Biologic agents have revolutionized the treatment of many systemic rheumatic diseases. They have provided an effective treatment option to many patients with previously intractable disease. When utilized appropriately they also reduce disability and improve capacity to work and quality of life. However, the translation of these agents and their benefits to GCA has not been a smooth one. An overview of the current biologic treatment options assessed in GCA is shown in Table 1.

Tumour necrosis factor alpha inhibitors

Tumour necrosis factor alpha (TNF-α) inhibitors were the first biologic agents to be evaluated in GCA. High tissue levels of TNF-α led to speculation that anti-TNF-α agents may be effective in GCA.[42] Subsequent RCTs failed to support this theorized benefit. An RCT of infliximab in 44 newly diagnosed GCA patients who were in glucocorticoid-induced remission demonstrated no significant benefit to infliximab use and the study was halted after an interim analysis. Indeed, while not reaching statistical significance both relapse rates and infection risk were higher in the infliximab group.[10] Adalimumab was also demonstrated to have no benefit in an RCT, with remission rates of 59% compared to 50% in the placebo group at week 26. There was a numerically lower risk of adverse events in the adalimumab group in this study but this did not reach clinical or statistical significance.[9] A small RCT of the soluble TNF receptor fusion protein etanercept in 17 patients suggested that this may potentially be a more effective method of targeting TNF-α in this population than with a monoclonal antibody. A numerically greater amount of etanercept treated patients (50% *versus* 12%) were in glucocorticoid-free remission at 12 months and the cumulatively prednisolone dose was significantly lower in this group.[43] However, the small size of this study and the lack of any subsequent large-scale studies of etanercept mean that the results must be interpreted with caution. Overall, the weight of evidence suggests that TNF-α inhibitors are ineffective in GCA.

Tocilizumab

Tocilizumab is a monoclonal antibody against the interleukin-6 receptor and is widely utilized in rheumatoid arthritis. Interleukin-6 has emerged as an attractive therapeutic target in GCA. This is based on reports of increased levels of IL-6 mRNA expression in inflamed temporal arteries and of elevated serum IL-6 levels in patients with active GCA.[42,44,45] However, this must be balanced against conflicting evidence from translational research showing that IL-6 does not stimulate pro-inflammatory cytokines in an *ex vivo* temporal artery biopsy model.[46] It is also concerning that lower IL-6 levels have been shown to have a clinical association with cranial ischaemic complications.[47] Coupled with our knowledge of the hypothesized dual T-cell pathway in GCA, this raises concerns that IL-6 blockade may address the T_H17 cell pathway but leave unchecked the T_H1 cell pathway.[48] Recent translational work, however, has shown that IL-6 may exert effects on the T-regulatory cell population in GCA, normalizing the phenotype and function of these cells in GCA.[49] This suggests that IL-6 blockade has the potential to exert effects outside of the direct targeting of the T_H17 cell pathway. Work from our group has uncovered an additional potential role for IL-6 as an effector cytokine in the T_H1 pathway.[41] Two RCTs of tocilizumab in GCA have reported extremely encouraging data regarding reduction in relapse rates and cumulative glucocorticoid doses. In the phase II study by Villiger and colleagues, 85% of tocilizumab patients achieved relapse-free survival at week 52 compared to 20% in the placebo group. This significant reduction in relapses was accompanied by a significant reduction in cumulative glucocorticoid dose; 43 mg/kg *versus* 110 mg/kg at week 52.[50] In the phase III GIACTA study, sustained remission rates at week 52 were 53% in tocilizumab-treated patients compared to 17% in glucocorticoid monotherapy, while the cumulative glucocorticoid dose was reduced by 50% in tocilizumab-treated patients.[51] The tocilizumab-treated patients in both of these studies received a shorter glucocorticoid duration than would commonly be used in clinical practice; while the 52-week glucocorticoid monotherapy arm of the GIACTA study is more comparable to standard glucocorticoid regimes there still exists a lack of clarity regarding the optimum glucocorticoid regime to use in combination with tocilizumab. It would provide further reassurance if the limited imaging performed as part of these

Table 1. Biologic agents in giant cell arteritis.

Biologic	Target	Level of evidence	Study results	Study limitations
Tocilizumab	IL-6	Two RCTs	Villiger *et al.* 30 patients 77% new onset Relapse-free week 52 85% tocilizumab + GC 20% GC alone GIACTA 251 patients 47% new onset Remission week 52 Tocilizumab weekly + 26 weeks GC 56% Tocilizumab every 2 weeks + 26 weeks GC 53% 26 weeks GC alone 14% 52 weeks GC alone 18%	Villiger *et al.* Single centre Small numbers Not blinded to C-reactive protein results GCs stopped after 6 months – shorter duration than usual No discontinuation data Limited imaging data GIACTA No discontinuation data Lack of imaging data Short duration of follow up Concern that vascular disease may progress despite clinical remission
Sirukumab	IL-6	RCT	Commenced but cancelled	
Abatacept	T-cell	RCT	41 patients 56% new onset Abatacept induction for all Randomized at month 3 to abatacept + GC *versus* GC alone Relapse-free week 52 Abatacept + GC 48% GC alone 31%	Modest effect All received abatacept Abatacept ineffective in Takayasu's arteritis
Ustekinumab	IL-12/IL-23	Open-label study	25 patients All refractory GCA Median GC dose decreased from 20 mg to 5 mg at week 52 No relapses on ustekinumab Imaging evidence of improvement	Unblinded No control group Small numbers Single centre
Adalimumab	TNF-α	RCT	70 patients All new onset Remission week 26 GC + adalimumab 59% GC alone 50%	New-onset patients only Excluded ischaemic manifestations

(Continued)

Table 1. (Continued)

Biologic	Target	Level of evidence	Study results	Study limitations
Infliximab	TNF-α	RCT	44 patients All new onset Relapse-free 52 weeks Infliximab + GC 43% GC alone 50%	Small numbers Study terminated early New-onset patients only
Etanercept	TNF-α	RCT	17 patients All in remission on GC with GC-related adverse events GC remission week 52 Etanercept + GC 50% GC alone 22%	Small numbers High discontinuation rate – 11/19 patients
Anakinra	IL-1β	Case series	Three refractory GCA patients, remission in all three	Case report data only; RCT planned
Gevokizumab	IL-1β	RCT	Commenced but cancelled	
Rituximab	B-cells	Case reports	Effective in two refractory cases	Case report data only
Baricitinib	JAK	Open-label study recruiting		
Upadacitinib	JAK	RCT planned		
Tofacitinib	JAK	Laboratory data only		

GC, glucocorticoids, GCA, giant cell arteritis; RCT, randomized controlled trial.

two studies demonstrated radiographic improvement of vasculitis. The MR angiography (MRA) results from the phase II trial have been reported and demonstrated incomplete suppression of MRA evidence of vasculitis, the clinical relevance of which remains to be determined.[52] The concerns raised from translational work regarding the potential for unchecked vasculitis and ischaemic complications to occur in clinically well patients is supported by some evidence from uncontrolled clinical studies. These include widespread vasculitis in a tocilizumab-treated patient in the open-label study by Unizony and colleagues, and evidence of progression of large vessel vasculitis in two Takayasu's arteritis patients treated with tocilizumab despite clinical and serological improvement.[53,54] Further data from the two RCTs are awaited. An RCT of an IL-6 monoclonal antibody, sirukumab (ClinicalTrials.gov identifier: NCT02531633), commenced recruitment but has now been cancelled.

Abatacept

Abatacept is a T-cell modulator, an effect achieved through inhibition of co-stimulation. It does this by binding to the CD80/CD86 molecule, preventing it from providing the second signal required for T-cell activation. Abatacept is theoretically attractive in GCA as both limbs of the proposed pathogenic model are helper T-cell based, T_H1 and T_H17 respectively playing central roles. In an RCT in GCA, abatacept in combination with glucocorticoids resulted in an increase in relapse-free survival at 12 months, from 31% to 48%, compared to glucocorticoid monotherapy.[55] Interpreting these results is complicated by the trial design, in which all patients received abatacept for the first 12 weeks, followed by randomization to continuing or withdrawing abatacept after this point. The small improvement in outcome in GCA patients coupled with the lack of efficacy in an RCT in Takayasu's arteritis is discouraging, and a planned phase III RCT has been withdrawn.[56] Therefore, at the present time there exists preliminary RCT evidence that abatacept is effective in GCA, but this effect appears to be modest.

Ustekinumab

Ustekinumab is a human IgG1 kappa monoclonal antibody developed using human Ig transgenic mice.[57] Ustekinumab blocks both IL-12 and IL-23 activity by binding to the common p40 subunit shared by both cytokines.[58,59] Ustekinumab was originally developed with the sole goal of targeting IL-12, prior to the recognition of the functional importance of IL-23.[58] It binds to IL-12 and IL-23 equally, preventing binding to their receptor complexes on the surfaces of T-lymphocytes and NK cells.[57] Thus, although ustekinumab was initially developed to target IL-12, it has emerged as a first-in-class dual cytokine inhibitor.[58] Ustekinumab is functionally unable to bind to IL-12 or IL-23 that have already bound to receptors and so is unlikely to participate in Fc effector functions such as antibody-dependent cell-mediated cytotoxicity.[57] Ustekinumab is FDA- and EMA-approved for use in the treatment of psoriasis and psoriatic arthritis.[60] This followed evidence of efficacy from phase III trials in both diseases.[61–64] It has also demonstrated clinical efficacy in the treatment of refractory Crohn's disease.[65] The hypothesized dual role of IL-12 and IL-23 in GCA makes ustekinumab a potentially attractive treatment option in this disease. A prospective open-label study of ustekinumab was performed in 25 patients with GCA.[66,67] All patients had refractory disease, defined as an inability to taper glucocorticoids below a certain fixed dose, or multiple relapses on tapering glucocorticoids. They had also failed a median of one previous steroid-sparing agent. Ustekinumab appeared to be efficacious in treating these patients, with a reduction in median prednisolone dose from 20 mg to 5 mg ($p < 0.001$), and a significant reduction in median C-reactive protein from 12.9 mg/L to 6 mg/L ($p = 0.006$). No patients had a flare of GCA while treated with ustekinumab, and one-quarter of patients were able to stop glucocorticoids entirely. CT angiography demonstrated a radiographic correlate of the clinical findings with improvement in radiographic large vessel vasculitis in all cases and full resolution in 50% of cases. There were no unexpected adverse events seen in the ustekinumab-treated patients. Three patients discontinued ustekinumab over the course of the study due to adverse events, with two of these subsequently having polymyalgic flares of GCA at 4 and 5 months respectively after stopping ustekinumab. The results from this study are certainly encouraging; however, it was an open-label study with no control group, and therefore an RCT of ustekinumab in GCA is warranted before it can be recommended for routine use.

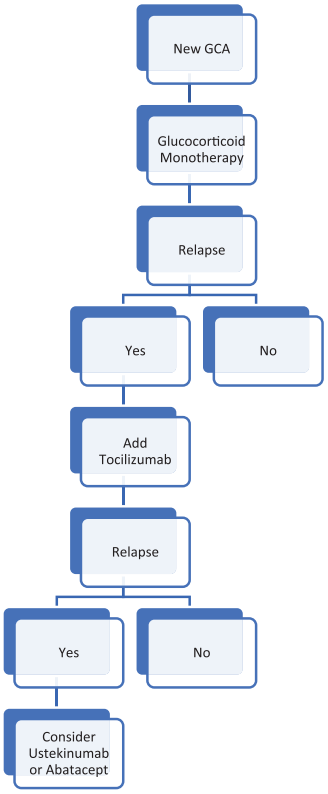

Figure 2. Suggested treatment algorithm in GCA.

Other agents

A number of other agents have been utilized in GCA and reported in case reports and case series. The successful use of interleukin-1β blockade with anakinra has been reported in three patients with GCA.[68] An RCT of anakinra (ClinicalTrials.gov identifier: NCT02902731) is currently planned. An RCT of another agent targeting interleukin-1β, gevokizumab, was commenced but subsequently cancelled. Efficacy of the anti-CD20 agent rituximab in refractory GCA has been reported in two case reports; while the pathogenic model of GCA mainly emphasizes the importance of T-cells, there are a number of studies that support a potential role for B-cells in GCA.[69–71]

As many of the cytokines implicated in GCA, including IL-6, IL-12 and IL-23, operate through JAK-STAT pathways, JAK inhibitors are an attractive potential treatment option. There is supportive basic scientific data for the efficacy of this approach with tofacitinib.[72] A small open-label pilot study of another JAK inhibitor, baricitinib, is currently recruiting participants (ClinicalTrials.gov identifier: NCT03026504). A third JAK inhibitor, upadacitinib, is also planned for an RCT (ClinicalTrials.gov identifier: NCT03725202).

Treatment approach in GCA in 2018

Integrating this new emerging evidence on the efficacy of biologic agents into a current treatment approach in GCA requires careful consideration. At present the authors would caution against the routine use of biologics in patients with new-onset GCA. While the emerging data, especially for tocilizumab, are highly promising, we still require further information particularly regarding the long-term efficacy and safety of these agents. It is reasonable to consider the institution of biologic agents in GCA patients who relapse while tapering glucocorticoids; whether the first or second relapse should be the trigger for this is unclear at present. The data supporting the use of biologic agents in GCA are strongest for tocilizumab. The use of other biologic agents, such as abatacept or ustekinumab, should probably be reserved for research settings and for those patients who have contraindications to or relapse on tocilizumab. The authors present a purely personal treatment algorithm for GCA in Figure 2. The treatment of GCA is a dynamic area at present and given the limited evidence currently available, this treatment approach is predominantly based on expert opinion and so must be used with caution and reviewed in the light of emerging data.

Conclusion

The treatment of GCA has been based almost entirely on glucocorticoids for nearly 70 years. In that time, multiple other agents have been used with limited success. Emerging evidence suggests that biologic agents, particularly tocilizumab, may open up new treatment approaches. Further evidence is needed before they can be recommended for routine use in patients with GCA.

Funding

The author(s) received no financial support for the research, authorship, and/or publication of this article.

Conflict of interest statement

The author(s) declared no potential conflicts of interest with respect to the research, authorship, and/or publication of this article.

ORCID iD

Richard Conway https://orcid.org/0000-0003-2538-3362

References

1. Crowson CS, Matteson EL, Myasoedova E, *et al*. The lifetime risk of adult-onset rheumatoid arthritis and other inflammatory autoimmune rheumatic diseases. *Arthritis Rheum* 2011; 63: 633–639.
2. Jennette JC, Falk RJ, Bacon PA, *et al*. 2012 Revised International Chapel Hill Consensus Conference nomenclature of vasculitides. *Arthritis Rheum* 2013; 65: 1–11.
3. Singh AG, Kermani TA, Crowson CS, *et al*. Visual manifestations in giant cell arteritis: trend over 5 decades in a population-based cohort. *J Rheumatol* 2015; 42: 309–315.
4. Nuenninghoff DM, Hunder GG, Christianson TJ, *et al*. Mortality of large-artery complication (aortic aneurysm, aortic dissection, and/or large-artery stenosis) in patients with giant cell arteritis: a population-based study over 50 years. *Arthritis Rheum* 2003; 48: 3532–3537.
5. Nuenninghoff DM, Hunder GG, Christianson TJ, *et al*. Incidence and predictors of large-artery complication (aortic aneurysm, aortic dissection, and/or large-artery stenosis) in patients with giant cell arteritis: a population-based study over 50 years. *Arthritis Rheum* 2003; 48: 3522–3531.
6. Weyand CM and Goronzy JJ. Immune mechanisms in medium and large-vessel vasculitis. *Nat Rev Rheumatol* 2013; 9: 731–740.
7. Weyand CM, Younge BR and Goronzy JJ. IFN-gamma and IL-17: the two faces of T-cell pathology in giant cell arteritis. *Curr Opin Rheumatol* 2011; 23: 43–49.
8. Mahr AD, Jover JA, Spiera RF, *et al*. Adjunctive methotrexate for treatment of giant cell arteritis: an individual patient data meta-analysis. *Arthritis Rheum* 2007; 56: 2789–2797.
9. Seror R, Baron G, Hachulla E, *et al*. Adalimumab for steroid sparing in patients with giant-cell arteritis: results of a multicentre randomised controlled trial. *Ann Rheum Dis* 2014; 73: 2074–2081.
10. Hoffman GS, Cid MC, Rendt-Zagar KE, *et al*. Infliximab for maintenance of glucocorticosteroid-induced remission of giant cell arteritis: a randomized trial. *Ann Intern Med* 2007; 146: 621–630.
11. Chandran A, Udayakumar PD, Kermani TA, *et al*. Glucocorticoid usage in giant cell arteritis over six decades (1950 to 2009). *Clin Exp Rheumatol* 2015; 33(2 Suppl. 89): S-98-102.
12. Proven A, Gabriel SE, Orces C, *et al*. Glucocorticoid therapy in giant cell arteritis: duration and adverse outcomes. *Arthritis Rheum* 2003; 49: 703–708.
13. Labarca C, Koster MJ, Crowson CS, *et al*. Predictors of relapse and treatment outcomes in biopsy-proven giant cell arteritis: a retrospective cohort study. *Rheumatology (Oxford)* 2016; 55: 347–356.
14. Boes CJ. Bayard Horton's clinicopathological description of giant cell (temporal) arteritis. *Cephalalgia* 2007; 27: 68–75.
15. Shick RM, Baggenstoss AH, Fuller BF, *et al*. Effects of cortisone and ACTH on periarteritis nodosa and cranial arteritis. *Proc Staff Meet Mayo Clin* 1950; 25: 492–494.
16. Mukhtyar C, Guillevin L, Cid MC, *et al*. EULAR recommendations for the management of large vessel vasculitis. *Ann Rheum Dis* 2009; 68: 318–323.
17. Dasgupta B, Borg FA, Hassan N, *et al*. BSR and BHPR guidelines for the management of giant cell arteritis. *Rheumatology (Oxford)* 2010; 49: 1594–1597.
18. Buttgereit F, Dejaco C, Matteson EL, *et al*. Polymyalgia rheumatica and giant cell arteritis: a systematic review. *JAMA* 2016; 315: 2442–2458.
19. Weyand CM, Kaiser M, Yang H, *et al*. Therapeutic effects of acetylsalicylic acid in giant cell arteritis. *Arthritis Rheum* 2002; 46: 457–466.
20. Ostberg G. Morphological changes in the large arteries in polymyalgia arteritica. *Acta Med Scand Suppl* 1972; 533: 135–159.
21. Maleszewski JJ, Younge BR, Fritzlen JT, *et al*. Clinical and pathological evolution of giant cell arteritis: a prospective study of follow-up temporal artery biopsies in 40 treated patients. *Mod Pathol* 2017; 30: 788–796.
22. Evans JM, O'Fallon WM and Hunder GG. Increased incidence of aortic aneurysm and dissection in giant cell (temporal) arteritis. A population-based study. *Ann Intern Med* 1995; 122: 502–507.
23. Smolen JS, Landewe R, Breedveld FC, *et al*. EULAR recommendations for the management of rheumatoid arthritis with synthetic and biological disease-modifying antirheumatic drugs: 2013 update. *Ann Rheum Dis* 2014; 73: 492–509.
24. Singh JA, Saag KG, Bridges SL Jr, *et al*. 2015 American College of Rheumatology guideline for the treatment of rheumatoid arthritis. *Arthritis Rheumatol (Hoboken, NJ)* 2016; 68: 1–26.
25. Food and Drug Administration. *Methotrexate prescribing information*. Food and Drug Administration, 2014, https://www.accessdata.fda.gov/drugsatfda_docs/label/2016/008085s066lbl.pdf

26. Spiera RF, Mitnick HJ, Kupersmith M, *et al*. A prospective, double-blind, randomized, placebo controlled trial of methotrexate in the treatment of giant cell arteritis (GCA). *Clin Exp Rheumatol* 2001; 19: 495–501.

27. Jover JA, Hernandez-Garcia C, Morado IC, *et al*. Combined treatment of giant-cell arteritis with methotrexate and prednisone: a randomized, double-blind, placebo-controlled trial. *Ann Intern Med* 2001; 134: 106–114.

28. Hoffman GS, Cid MC, Hellmann DB, *et al*. A multicenter, randomized, double-blind, placebo-controlled trial of adjuvant methotrexate treatment for giant cell arteritis. *Arthritis Rheum* 2002; 46: 1309–1318.

29. Diamantopoulos AP, Hetland H and Myklebust G. Leflunomide as a corticosteroid-sparing agent in giant cell arteritis and polymyalgia rheumatica: a case series. *Biomed Res Int* 2013; 2013: 120638.

30. Adizie T, Christidis D, Dharmapaliah C, *et al*. Efficacy and tolerability of leflunomide in difficult-to-treat polymyalgia rheumatica and giant cell arteritis: a case series. *Int J Clin Pract* 2012; 66: 906–909.

31. Loock J, Henes J, Kotter I, *et al*. Treatment of refractory giant cell arteritis with cyclophosphamide: a retrospective analysis of 35 patients from three centres. *Clin Exp Rheumatol* 2012; 30: S70–S76.

32. de Boysson H, Boutemy J, Creveuil C, *et al*. Is there a place for cyclophosphamide in the treatment of giant-cell arteritis? A case series and systematic review. *Semin Arthritis Rheum* 2013; 43: 105–112.

33. Quartuccio L, Maset M, De Maglio G, *et al*. Role of oral cyclophosphamide in the treatment of giant cell arteritis. *Rheumatology (Oxford)* 2012; 51: 1677–1686.

34. Ly KH, Dalmay F, Gondran G, *et al*. Steroid-sparing effect and toxicity of dapsone treatment in giant cell arteritis: a single-center, retrospective study of 70 patients. *Medicine* 2016; 95: e4974.

35. Dospinescu P, Karabayas M, Kidder D, *et al*. Mycophenolate mofetil versus methotrexate in the management of large vessel giant cell arteritis. *Ann Rheum Diseases* 2016; 75: 798.

36. De Silva M and Hazleman BL. Azathioprine in giant cell arteritis/polymyalgia rheumatica: a double-blind study. *Ann Rheum Diseases* 1986; 45: 136–138.

37. Sailler L, Lapeyre-Mestre M, Geffray L, *et al*. Adding hydroxychloroquine to prednisone does not improve the outcome in giant cell arteritis: a double blind randomized controlled trial. *Arthritis Rheum* 2009; 60: 1972.

38. Schaufelberger C, Andersson R and Nordborg E. No additive effect of cyclosporin A compared with glucocorticoid treatment alone in giant cell arteritis: results of an open, controlled, randomized study. *Br J Rheumatol* 1998; 37: 464–465.

39. Schaufelberger C, Mollby H, Uddhammar A, *et al*. No additional steroid-sparing effect of cyclosporine A in giant cell arteritis. *Scand J Rheumatol* 2006; 35: 327–329.

40. Weyand CM, Liao YJ and Goronzy JJ. The immunopathology of giant cell arteritis: diagnostic and therapeutic implications. *J Neuroophthalmol* 2012; 32: 259–265.

41. Conway R, O'Neill L, McCarthy GM, *et al*. Interleukin 12 and interleukin 23 play key pathogenic roles in inflammatory and proliferative pathways in giant cell arteritis. *Ann Rheum Dis* 2018; 77: 1815–1824.

42. Hernandez-Rodriguez J, Segarra M, Vilardell C, *et al*. Tissue production of pro-inflammatory cytokines (IL-1beta, TNFalpha and IL-6) correlates with the intensity of the systemic inflammatory response and with corticosteroid requirements in giant-cell arteritis. *Rheumatology (Oxford)* 2004; 43: 294–301.

43. Martinez-Taboada VM, Rodriguez-Valverde V, Carreno L, *et al*. A double-blind placebo controlled trial of etanercept in patients with giant cell arteritis and corticosteroid side effects. *Ann Rheum Dis* 2008; 67: 625–630.

44. Weyand CM, Hicok KC, Hunder GG, *et al*. Tissue cytokine patterns in patients with polymyalgia rheumatica and giant cell arteritis. *Ann Intern Med* 1994; 121: 484–491.

45. Dasgupta B and Panayi GS. Interleukin-6 in serum of patients with polymyalgia rheumatica and giant cell arteritis. *Br J Rheumatol* 1990; 29: 456–458.

46. O'Neill L, McCormick J, Gao W, *et al*. Interleukin 6 does not upregulate pro inflammatory cytokine expression in an ex-vivo model of giant cell arteritis. *Arthritis Rheumatol*. 2014; 66: S391.

47. Hernandez-Rodriguez J, Segarra M, Vilardell C, *et al*. Elevated production of interleukin-6 is associated with a lower incidence of disease-related ischemic events in patients with giant-cell arteritis: angiogenic activity of interleukin-6 as a potential protective mechanism. *Circulation* 2003; 107: 2428–2434.

48. Deng J, Younge BR, Olshen RA, *et al*. Th17 and Th1 T-cell responses in giant cell arteritis. *Circulation* 2010; 121: 906–915.

49. Miyabe C, Miyabe Y, Strle K, *et al*. An expanded population of pathogenic regulatory T cells in giant cell arteritis is abrogated by IL-6 blockade therapy. *Ann Rheum Dis* 2016; 76: 898–905.

50. Villiger PM, Adler S, Kuchen S, *et al*. Tocilizumab for induction and maintenance of remission in giant cell arteritis: a phase 2, randomised, double-blind, placebo-controlled trial. *Lancet* 2016; 387: 1921–1927.

51. Stone JH, Tuckwell K, Dimonaco S, *et al*. Trial of tocilizumab in giant-cell arteritis. *N Engl J Med* 2017; 377: 317–328.

52. Reichenbach S, Adler S, Bonel H, *et al*. Magnetic resonance angiography in giant cell arteritis: results of a randomized controlled trial of tocilizumab in giant cell arteritis. *Rheumatology (Oxford)* 2018; 57: 982–986.

53. Xenitidis T, Horger M, Zeh G, *et al*. Sustained inflammation of the aortic wall despite tocilizumab treatment in two cases of Takayasu arteritis. *Rheumatology (Oxford)* 2013; 52: 1729–1731.

54. Unizony S, Arias-Urdaneta L, Miloslavsky E, *et al*. Tocilizumab for the treatment of large-vessel vasculitis (giant cell arteritis, Takayasu arteritis) and polymyalgia rheumatica. *Arthritis Care Res (Hoboken)* 2012; 64: 1720–1729.

55. Langford CA, Cuthbertson D, Ytterberg SR, *et al*. A randomized, double-blind trial of abatacept (CTLA-4Ig) for the treatment of giant cell arteritis. *Arthritis Rheumatol* 2017; 69: 837–845.

56. Langford CA, Cuthbertson D, Ytterberg SR, *et al*. A randomized, double-blind trial of abatacept (CTLA4-ig) for the treatment of Takayasu's arteritis. *Arthritis Rheumatol* 2017; 69: 846–853.

57. Benson JM, Peritt D, Scallon BJ, *et al*. Discovery and mechanism of ustekinumab: a human monoclonal antibody targeting interleukin-12 and interleukin-23 for treatment of immune-mediated disorders. *mAbs* 2011; 3: 535–545.

58. Benson JM, Sachs CW, Treacy G, *et al*. Therapeutic targeting of the IL-12/23 pathways: generation and characterization of ustekinumab. *Nat Biotechnol* 2011; 29: 615–624.

59. Luo J, Wu SJ, Lacy ER, *et al*. Structural basis for the dual recognition of IL-12 and IL-23 by ustekinumab. *J Mol Biol* 2010; 402: 797–812.

60. Gossec L, Smolen JS, Ramiro S, *et al*. European League Against Rheumatism (EULAR) recommendations for the management of psoriatic arthritis with pharmacological therapies: 2015 update. *Ann Rheum Dis* 2016; 75: 499–510.

61. Papp KA, Langley RG, Lebwohl M, *et al*. Efficacy and safety of ustekinumab, a human interleukin-12/23 monoclonal antibody, in patients with psoriasis: 52-week results from a randomised, double-blind, placebo-controlled trial (PHOENIX 2). *Lancet* 2008; 371: 1675–1684.

62. McInnes IB, Kavanaugh A, Gottlieb AB, *et al*. Efficacy and safety of ustekinumab in patients with active psoriatic arthritis: 1 year results of the phase 3, multicentre, double-blind, placebo-controlled PSUMMIT 1 trial. *Lancet* 2013; 382: 780–789.

63. Leonardi CL, Kimball AB, Papp KA, *et al*. Efficacy and safety of ustekinumab, a human interleukin-12/23 monoclonal antibody, in patients with psoriasis: 76-week results from a randomised, double-blind, placebo-controlled trial (PHOENIX 1). *Lancet* 2008; 371: 1665–1674.

64. Gottlieb A, Menter A, Mendelsohn A, *et al*. Ustekinumab, a human interleukin 12/23 monoclonal antibody, for psoriatic arthritis: randomised, double-blind, placebo-controlled, crossover trial. *Lancet* 2009; 373: 633–640.

65. Sandborn WJ, Gasink C, Gao LL, *et al*. Ustekinumab induction and maintenance therapy in refractory Crohn's disease. *N Engl J Med* 2012; 367: 1519–1528.

66. Conway R, O'Neill L, O'Flynn E, *et al*. Ustekinumab for the treatment of refractory giant cell arteritis. *Ann Rheum Dis* 2016; 75: 1578–1579.

67. Conway R, O'Neill L, Gallagher P, *et al*. Ustekinumab for refractory giant cell arteritis: a prospective 52-week trial. *Semin Arthritis Rheum* 2018; 48: 523–528.

68. Ly KH, Stirnemann J, Liozon E, *et al*. Interleukin-1 blockade in refractory giant cell arteritis. *Joint Bone Spine* 2014; 81: 76–78.

69. van der Geest KS, Abdulahad WH, Chalan P, *et al*. Disturbed B cell homeostasis in newly diagnosed giant cell arteritis and polymyalgia rheumatica. *Arthritis Rheumatol* 2014; 66: 1927–1938.

70. Ciccia F, Rizzo A, Maugeri R, *et al*. Ectopic expression of CXCL13, BAFF, APRIL and LT-beta is associated with artery tertiary lymphoid organs in giant cell arteritis. *Ann Rheum Dis* 2017; 76: 235–243.

71. Graver JC, Sandovici M, Diepstra A, *et al*. Artery tertiary lymphoid organs in giant cell arteritis are not exclusively located in the media of temporal arteries. *Ann Rheum Dis* 2018; 77: e16.

72. Zhang H, Watanabe R, Berry GJ, *et al*. Inhibition of JAK-STAT signaling suppresses pathogenic immune responses in medium and large vessel vasculitis. *Circulation* 2018; 137: 1934–1948.

Visit SAGE journals online journals.sagepub.com/home/tab

SAGE journals